



Occipital activation in glyceryl trinitrate induced migraine with visual aura

S Afridi, H Kaube and P J Goadsby

J. Neurol. Neurosurg. Psychiatry 2005;76;1158-1160
doi:10.1136/jnp.2004.050633

Updated information and services can be found at:
<http://jnp.bmj.com/cgi/content/full/76/8/1158>

These include:

References

This article cites 25 articles, 7 of which can be accessed free at:
<http://jnp.bmj.com/cgi/content/full/76/8/1158#BIBL>

1 online articles that cite this article can be accessed at:
<http://jnp.bmj.com/cgi/content/full/76/8/1158#otherarticles>

Rapid responses

One rapid response has been posted to this article, which you can access for free at:
<http://jnp.bmj.com/cgi/content/full/76/8/1158#responses>

You can respond to this article at:
<http://jnp.bmj.com/cgi/eletter-submit/76/8/1158>

Email alerting service

Receive free email alerts when new articles cite this article - sign up in the box at the top right corner of the article

Topic collections

Articles on similar topics can be found in the following collections

[Drugs: central nervous system \(not psychiatric\)](#) (269 articles)
[Migraine](#) (96 articles)

Notes

To order reprints of this article go to:
<http://www.bmjournals.com/cgi/reprintform>

To subscribe to *Journal of Neurology, Neurosurgery, and Psychiatry* go to:
<http://www.bmjournals.com/subscriptions/>

SHORT REPORT

Occipital activation in glyceryl trinitrate induced migraine with visual aura

S Afridi, H Kaube, P J Goadsby*J Neurol Neurosurg Psychiatry* 2005;76:1158–1160. doi: 10.1136/jnp.2004.050633

A case of migraine is presented with visual aura triggered on two separate occasions by glyceryl trinitrate (GTN). Positron emission tomography was carried out during the second triggering session. Activation in the primary visual area of the occipital cortex was demonstrated during the aura. This is the first published case of migraine aura triggered reproducibly by GTN.

Migraine is a common and disabling disorder¹ with an estimated prevalence of 10–15%.^{2,3} A small but significant proportion of these have migraine with aura, most commonly in the form of visual disturbances,⁴ such as scintillating scotoma. Leao⁵ first described the phenomenon of spreading depression when he found that noxious stimulation of rabbit cerebral cortex produced a spreading decrease in electrical activity, moving at a rate of 2–3 mm/min. This rate corresponds well with the propagation of visual aura.⁶ It has been proposed that this cortical spreading depression represents the neurobiological basis for migraine aura whereby neuronal activation and suppression are followed by corresponding vascular changes.⁷

It has been difficult to image patients with migraine aura because functional brain imaging is technically demanding and spontaneous attacks are unpredictable. While nitric oxide (NO) donors have long been recognised to trigger severe headache,⁸ and indeed to trigger migraine,⁹ they have generally not been recognised to trigger migraine aura, even in those who have had it spontaneously.¹⁰

CASE REPORT

A 54 year old male with episodic migraine with aura volunteered to participate in a positron emission tomography (PET) study in migraine. He had a history of migraine with aura as defined by the International Headache Society (IHS) criteria¹¹ since his teenage years, with a frequency of up to eight attacks per month, each lasting up to one day if left untreated. A typical attack would begin with visual aura in the form of bright, flashing zig-zag shapes moving around his visual field and rarely he experienced macropsia. The visual aura would last 10 to 20 minutes and would be followed by a left sided headache with associated nausea, photophobia, phonophobia, and aggravation by movement. His attacks were usually aborted within two hours with the use of zolmitriptan. He had no other significant medical conditions. His father also suffered with migraine with aura.

Glyceryl trinitrate triggering

An intravenous infusion of 0.5 µg/kg/min glyceryl trinitrate (GTN) was given over 20 minutes on two occasions separated by one week with the aim of inducing a migraine. On both occasions a migraine was successfully triggered, after

150 minutes and 165 minutes, respectively. The subject underwent PET scanning during the second session of GTN.

A visual aura typical of the subject's previous attacks was also triggered during both sessions of GTN. He described flashing bright zig-zag patterns spreading across his visual field lasting 10 minutes. He was unable to describe any laterality of the visual symptoms. The aura remained unchanged by eye closure. This was then followed by a left sided migrainous headache. Subcutaneous sumatriptan (6 mg) was then given to the subject and the migraine attack was successfully aborted.

PET scanning and analysis

The subject was scanned before the infusion, while pain-free, and during the aura and headache phases of migraine. He described the onset of the aura, and scanning of the aura phase began immediately following this description. PET was carried out with an ECAT EXACT HR+ scanning system (CTI Siemens, Knoxville, Tennessee, USA) in three dimensional mode with septa retracted. He had his eyes closed throughout the scanning sessions. An antecubital vein cannula was used to give the tracer (350 mBq of H₂¹⁵O). The activity was infused into subjects over 20 seconds at a rate of 10 ml/min. The data were acquired in one 90 second frame beginning five seconds before the peak of the head curve. The subject had a total of 12 scans, two of which were during the aura. The aura subsided during the second of the scans. The interval between scans was eight minutes. Attenuation correction was carried out with a transmission scan acquired at the beginning of each study. Images were reconstructed by filtered back projection into 63 image planes (separation 2.4 mm) and into a 128×128 pixel image matrix (pixel size 2.1×2.1 mm²). SPM99 (Wellcome Department of Imaging Neuroscience, <http://www.fil.ion.ucl.ac.uk/spm>) was used for data analysis.¹² Images were realigned with the first as the reference and then co-registered, and finally spatially normalised into the space defined by the atlas of Talairach and Tournoux.¹³ The normalised images were smoothed with a Gaussian filter of 10 mm full width at half maximum. Statistical parametric maps were derived with prespecified contrasts, comparing regional cerebral blood flow during aura versus rest. An uncorrected threshold of $p < 0.001$ was chosen for tabular and graphical reporting.

Analysis of the PET data revealed right sided occipital activation when comparing the two scans taken during the visual aura with those taken immediately before the GTN infusion (fig 1). The activation was in the primary visual region (V1) of the occipital cortex (Brodmann area 17). This area has a very high degree of retinotopic precision and orientation selectivity.¹⁴ No significant activation was observed in the V1 region of seven other patients with IHS

Abbreviations: GTN, glyceryl trinitrate; IHS, International Headache Society

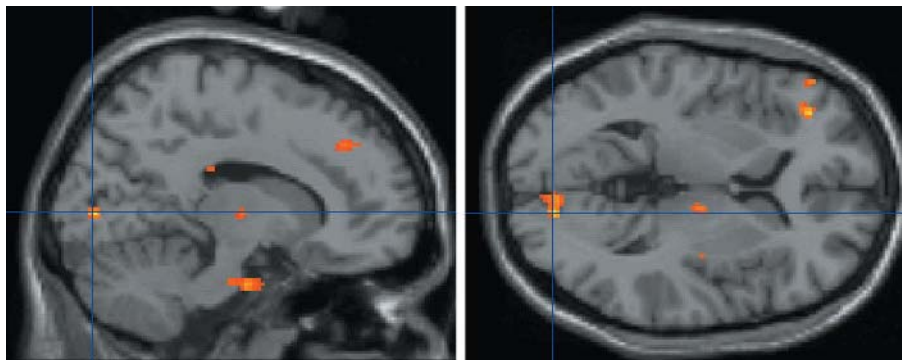


Figure 1 Right sided occipital activation during visual aura. The Talairach and Tournoux¹³ coordinates of peak activation within the cluster are (14, -82, 8). The z score at peak activation is 4.4 (uncorrected $p < 0.001$).

defined migraine with aura who developed migraine without aura following GTN administration.¹⁵

DISCUSSION

As far as we are aware there have not been any published reports of PET activation in the primary visual cortex during visual aura. Earlier studies using PET and single photon emission computed tomography (SPECT) showed spreading hypoperfusion in the occipital cortex in migraine with aura.^{16,17} More recently, functional MRI has been used in migraineurs to investigate occipital cortex activation during visual stimulation with a checker board. In one of these studies an initial increase in blood flow was demonstrated in the extrastriate cortex (V3A).⁶ This signal progressed across the occipital cortex (including V1) and was followed by diminution of the signal. The authors proposed that these changes represented cortical spreading depression. In a previous fMRI study¹⁸ the process was described in another subject with visually triggered visual aura. In this case it was initiated in the primary visual cortex and then spread anterolaterally. Unfortunately the relatively poor temporal resolution of PET did not allow us to follow the progression of the aura more closely in our case.

GTN is a nitric oxide (NO) donor which has previously been shown to trigger migraine attacks in migraineurs. In a study of 12 subjects with migraine with aura GTN was found to trigger an attack of migraine without aura in six of the subjects but failed to induce the aura in these.¹⁰ However, in a recent study by Sances and colleagues¹⁹ involving 197 migraineurs it was found that of the 22 subjects with migraine with aura, migraine without aura was triggered in six subjects and migraine with aura in three (13.6%). The success rate of the trigger was higher (82%) in the subjects with migraine without aura. Our patient was a participant in a study involving GTN triggering of migraine and was one of two patients in whom migraine aura was triggered.¹⁵ Unfortunately the second patient did not undergo PET scanning. In the aforementioned study migraine without aura was triggered in a further 12 patients with migraine with aura. The mechanism by which GTN triggers migraine is unclear but it is thought that the exogenous NO from the GTN may induce endogenous NO production. Animal studies have also revealed that cortical spreading depression, which is thought to be responsible for migraine aura in humans, elicits widespread release of NO and increased cortical concentrations of cyclic guanosine monophosphate (cGMP).²⁰

Other possible causes for the occipital activation in this patient include the possibility that he opened his eyes during the scanning, although the patient denies this and if this was the case then one would expect a much greater pattern of activation in the visual cortex than that observed. Another

possibility is that the GTN is responsible for vasodilatation in the occipital cortex. However, the region of activation is localised and unilateral and one would expect a GTN related flow change to be bilateral and generalised. In fact bilateral hypoperfusion rather than hyperperfusion has been documented in the occipital cortex following GTN administration to healthy controls.²¹ It is possible that some inherent neurovascular asymmetry exists in the brains of migraineurs which may alter the vascular response to GTN. However, this does not explain the lack of significant activation in the V1 region in any of the other patients with migraine with aura who received GTN infusions. It is also of interest to note that activation in V1 has been documented during visual mental imagery, in particular when the subjects are required to imagine high resolution detailed images.²²

Ours is the first case to show that aura can be triggered reproducibly by GTN, making it less likely that the aura was spontaneous or developed by chance in this situation. The fact that the site of activation was contralateral to the headache does not contradict our explanation for the findings, as we are proposing that the V1 activation is related to the aura and not the headache. Clinical and experimental observations²³⁻²⁵ have shown that aura symptoms are not always contralateral to headache and consequently aura associated changes in brain activation may be contralateral to headache. While some take the view that aura triggers headache,²⁶ others have argued for a dissociation.²⁷

In conclusion, we present evidence for the reproducibility of GTN as a trigger of migraine aura. While the number of patients who can have aura reliably re-triggered are small, such cases clearly exist and may offer insights into the neuroanatomical correlates of this fascinating clinical symptom.

Authors' affiliations

S Afridi, H Kaube, P J Goadsby, Headache Group, Institute of Neurology and The National Hospital for Neurology and Neurosurgery Queen Square, London WC1, UK

Competing interests: none declared

Correspondence to: Professor Peter J Goadsby, Headache Group, Institute of Neurology, Queen Square, London WC1N 3BG, UK, peterg@ion.ucl.ac.uk

Received 26 July 2004

In revised form 21 November 2004

Accepted 1 December 2004

REFERENCES

- 1 Menken M, Munsat TL, Toole JF. The global burden of disease study – implications for neurology. *Arch Neurol* 2000;**57**:418–20.

- 2 **Lipton RB**, Stewart WF, Diamond S, *et al*. Prevalence and burden of migraine in the United States: data from the American Migraine Study II. *Headache* 2001;**41**:646–57.
- 3 **Steiner TJ**, Scher AI, Stewart WF, *et al*. The prevalence and disability burden of adult migraine in England and their relationships to age, gender and ethnicity. *Cephalalgia* 2003;**23**:519–27.
- 4 **Rasmussen BK**, Olesen J. Migraine with aura and migraine without aura: an epidemiological study. *Cephalalgia* 1992;**12**:221–8.
- 5 **Leao AAP**. Spreading depression of activity in cerebral cortex. *J Neurophysiol* 1944;**7**:359–90.
- 6 **Hadjikhani N**, Sanchez del Rio M, Wu O, *et al*. Mechanisms of migraine aura revealed by functional MRI in human visual cortex. *Proc Natl Acad Sci USA* 2001;**98**:4687–92.
- 7 **Lauritzen M**. Pathophysiology of the migraine aura. The spreading depression theory. *Brain* 1994;**117**:199–210.
- 8 **Laws GL**. The effects of nitroglycerin upon those who manufacture it. *JAMA* 1898;**31**:793–4.
- 9 **Iversen H**. Human migraine models. *Cephalalgia* 2001;**21**:781–5.
- 10 **Christiansen I**, Thomsen LL, Daugaard D, *et al*. Glyceryl trinitrate induces attacks of migraine without aura in sufferers of migraine with aura. *Cephalalgia* 1999;**19**:660–7.
- 11 **Headache Classification Committee**. International Headache Society. The international classification of headache disorders, 2nd ed. *Cephalalgia* 2004;**24**(suppl 1):1–160.
- 12 **Frackowiak RSJ**, Friston KJ. Functional neuroanatomy of the human brain: positron emission tomography – a new neuroanatomical technique. *J Anat* 1994;**184**:211–25.
- 13 **Talairach J**, Tournoux P. *Coplanar stereotaxic atlas of the human brain*. New York: Thieme, 1988.
- 14 **Tootell RB**, Hadjikhani NK, Vanduffel W, *et al*. Functional analysis of primary visual cortex (V1) in humans. *Proc Natl Acad Sci USA* 1998;**95**:811–17.
- 15 **Afridi S**, Kaube H, Goadsby PJ. Glyceryl trinitrate triggers premonitory symptoms in migraineurs. *Pain* 2004;**110**:675–80.
- 16 **Olesen J**, Larsen B, Lauritzen M. Focal hyperemia followed by spreading oligemia and impaired activation of rCBF in classic migraine. *Ann Neurol* 1981;**9**:344–52.
- 17 **Woods RP**, Iacoboni M, Mazziotta JC. Bilateral spreading cerebral hypoperfusion during spontaneous migraine headache. *N Engl J Med* 1994;**331**:1689–92.
- 18 **Cao Y**, Welch KMA, Aurora S, *et al*. Functional MRI-BOLD of visually triggered headache in patients with migraine. *Arch Neurol* 1999;**56**:548–54.
- 19 **Sances G**, Tassorelli C, Pucci E, *et al*. Reliability of the nitroglycerin provocative test in the diagnosis of neurovascular headaches. *Cephalalgia* 2004;**24**:110–19.
- 20 **Read SJ**, Hirst WD, Upton N, *et al*. Cortical spreading depression produces increased cGMP levels in cortex and brain stem that is inhibited by tonabersat (SB-220453) but not sumatriptan. *Brain Res* 2001;**891**:69–77.
- 21 **Bednarczyk EM**, Wack DS, Kassab MY, *et al*. Brain blood flow in the nitroglycerin (GTN) model of migraine: measurement using positron emission tomography and transcranial Doppler. *Cephalalgia* 2002;**22**:749–57.
- 22 **Kosslyn SM**, Ganis G, Thompson WL. Neural foundations of imagery. *Nat Rev Neurosci* 2001;**2**:635–42.
- 23 **Olesen J**, Friberg L, Skyhoj-Olsen T, *et al*. Timing and topography of cerebral blood flow, aura, and headache during migraine attacks. *Ann Neurol* 1990;**28**:791–8.
- 24 **Selby G**, Lance JW. Observations on 500 cases of migraine and allied vascular headache. *J Neurol Neurosurg Psychiatry* 1960;**23**:23–32.
- 25 **Peatfield RC**, Rose FC. Prospective study of unilateral classical migraine. In: Rose FC, ed. *New advances in headache research*. 2. London: Smith-Gordon, 1991.
- 26 **Moskowitz MA**, Bolay H, Dalkara T. Deciphering migraine mechanisms: clues from familial hemiplegic migraine genotypes. *Ann Neurol* 2004;**55**:276–80.
- 27 **Goadsby PJ**. Migraine, aura and cortical spreading depression: why are we still talking about it? *Ann Neurol* 2001;**49**:4–6.